



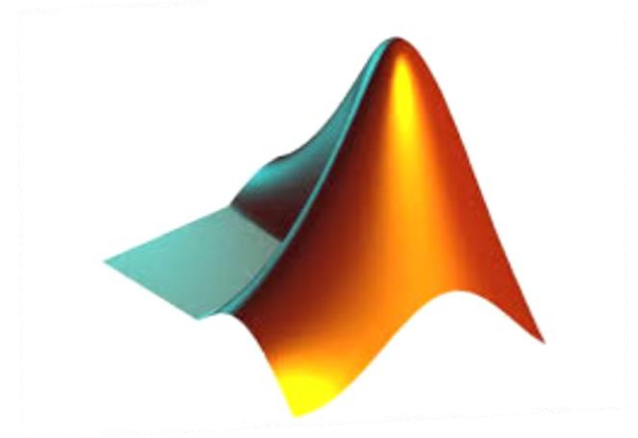
Study And Development Of Digital Image Processing Tool For Application Of Diabetic Retinopathy

Name: Ms. Jyoti Devidas Patil

mail ID: jyot.physics@gmail.com

Outline

1. Aims & Objective
2. Introduction
3. Classification Of Diabetic Retinopathy
4. MATLAB in Ophthalmology
5. Methodology & Process Flowchart
6. Social Impact & Challenges
7. Conclusion & Future Scope



Aim and Objective

Aim- Aim of this research is to develop **reliable and accurate** image processing and pattern recognition methods to be used as an automatic tool for the mass screening of diabetic retinopathy and to aid ophthalmologist's diagnosis.

Objectives-

- ❑ Recognize the importance of diabetic retinopathy as a public health problem
- ❑ To develop algorithms for detection of diabetic eye.
- ❑ To implement an automated detection tool of Diabetic Retinopathy using digital fundus images.
- ❑ To extract and detect the features such as Micro aneurysms, Retinal Haemorrhages , Cotton wool spots, Hard exudates and Neovascular textures which will determine two general classifications:
 - 1) Proliferative diabetic Retinopathy (abnormal (DR) eye).
 - 2) Non Proliferative diabetic Retinopathy (normal)

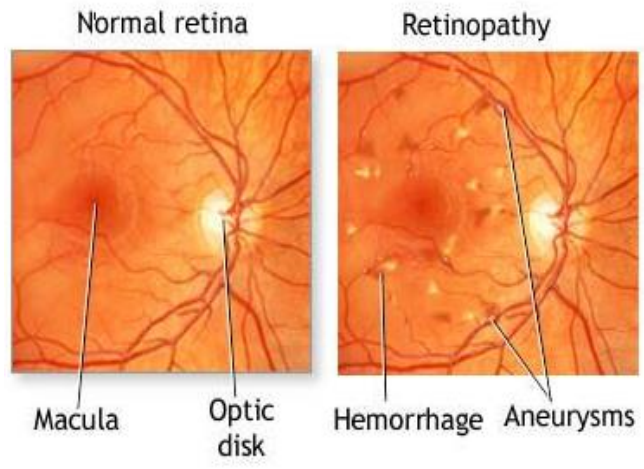
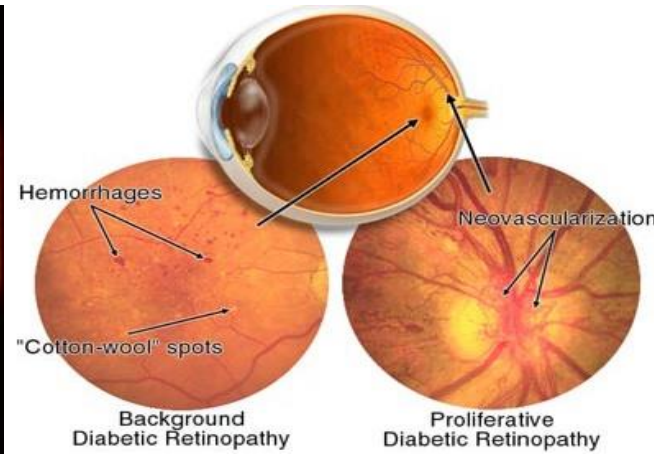
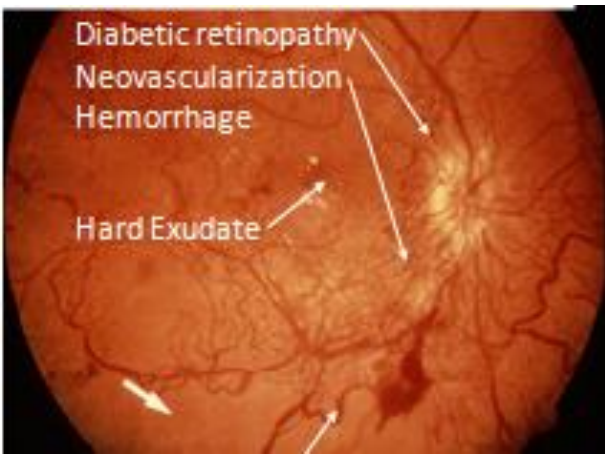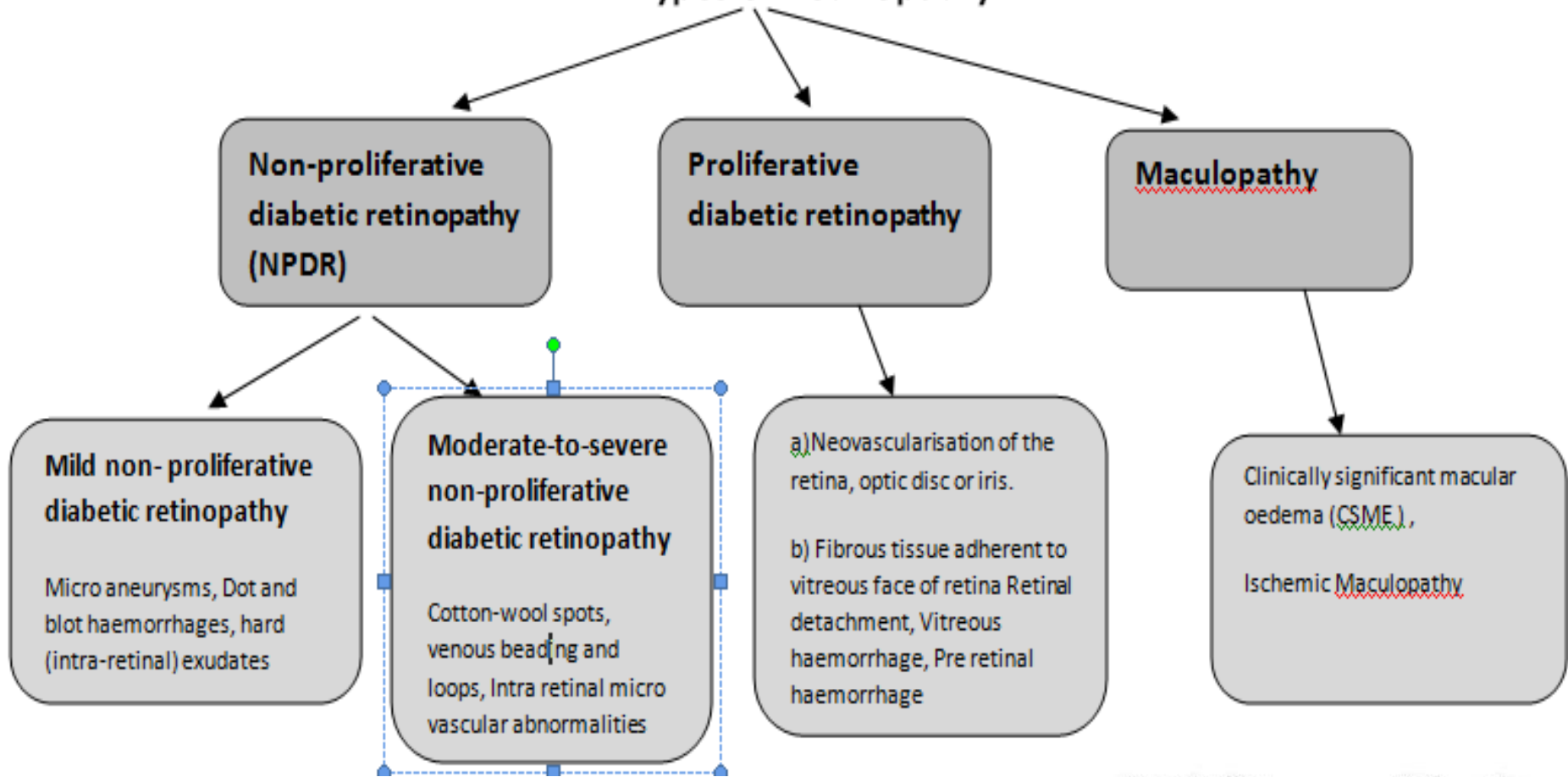
Introduction

Diabetic Retinopathy (DR):

People with diabetes can have an eye disease like diabetic retinopathy, results in swelling and leaking of blood vessels. Sometimes abnormal new blood vessels grow on the retina. All of these changes can steal your vision.

- This research detects the presence of abnormalities in the retina using **image processing techniques** by applying morphological processing to the fundus images to extract features such as **blood vessels, micro aneurysms, haemorrhages ,exudates and neo vascularization**.
- Then depending on the Area of these features are used for the detection of severity of Diabetic Retinopathy.

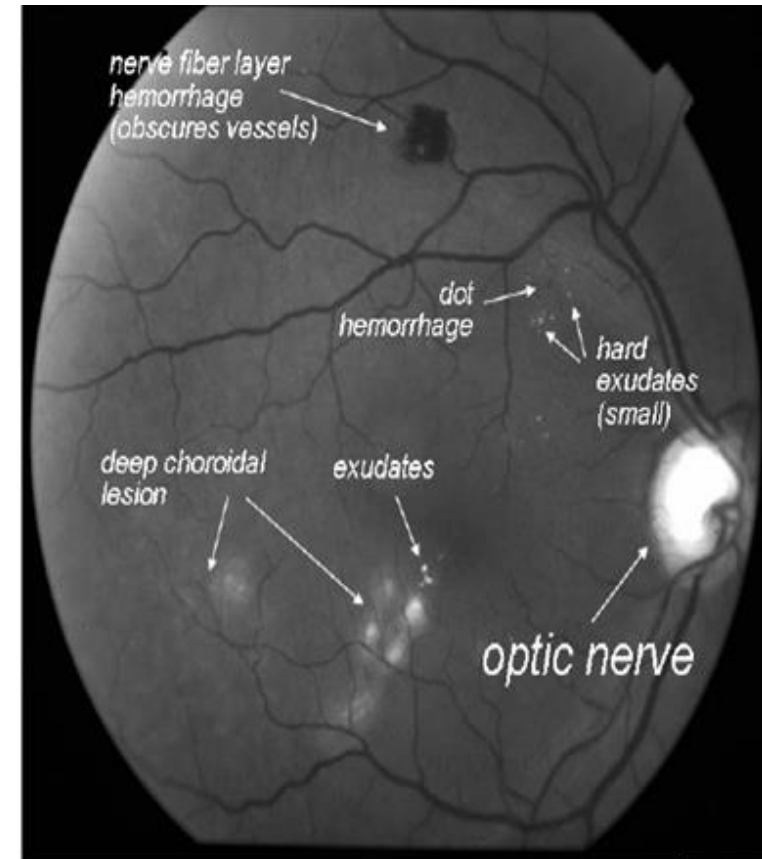
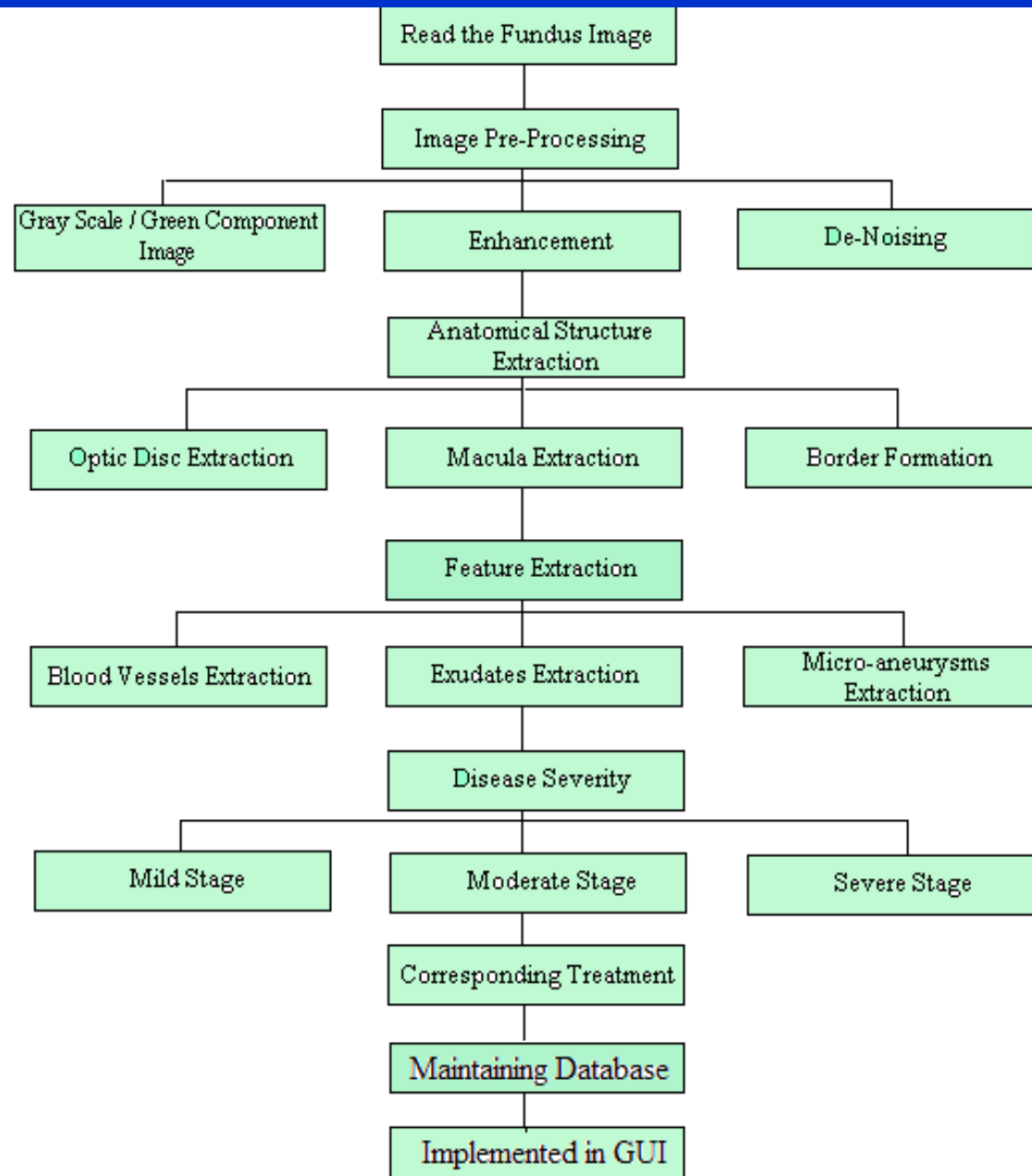
Types of Retinopathy



Tools used :

1. Median filters, Image range filter, Filtering, Gabor filtering
2. Threshold Techniques
3. Laplacian filters
4. Otsu's Method
5. contrast enhance
6. Image segmentation
7. Image enhancement methods like Adaptive Contrast Enhancement, Histogram equalization.
8. Segmentation-color Space Selection,
9. Statistical Measures,
10. Fuzzy Gaussian Filter Tool,
11. Sobel and canny edge detection
12. Contrast Limited Adaptive Histogram Equalization (CLAHE)
13. Walter–klein contrast enhancement

Diabetic Retinopathy Detection



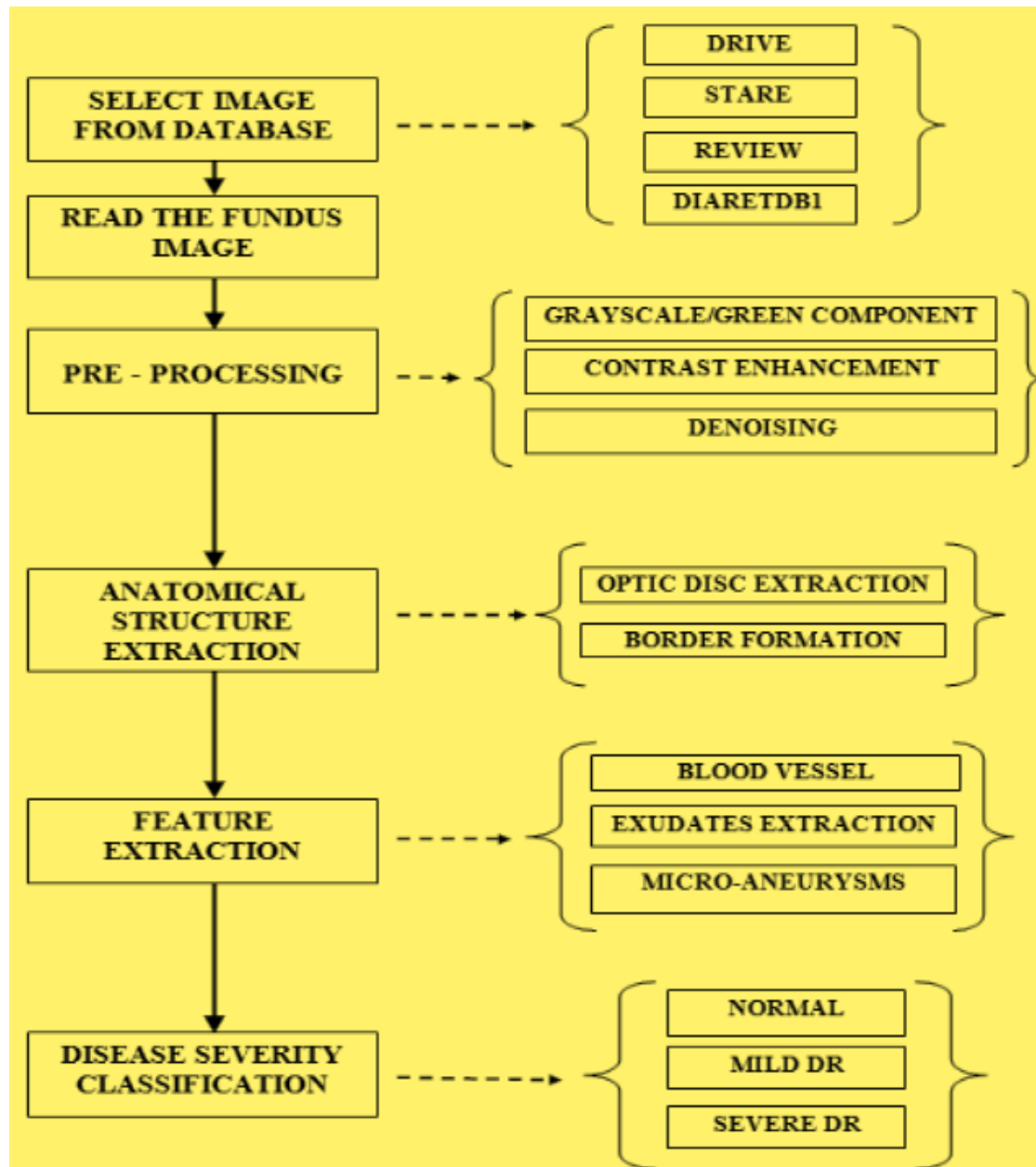
Red-free fundus image showing the optic nerve, vascular arcades, and a variety of lesions.

Methodology

Extract & detect the features such as blood vessels, micro-aneurysms & exudates, will determine classification : normal or abnormal DR eye.

➤ **Corresponding Steps :**

- Read Input Image From Fundus Camera
- Image Pre-processing
- Anatomical Structure Extraction
- Feature Extraction
- Disease Severity
- Corresponding Treatment
- Maintaining Database & GUI



Methodology:

- **WALTER–KLEIN CONTRAST ENHANCEMENT**

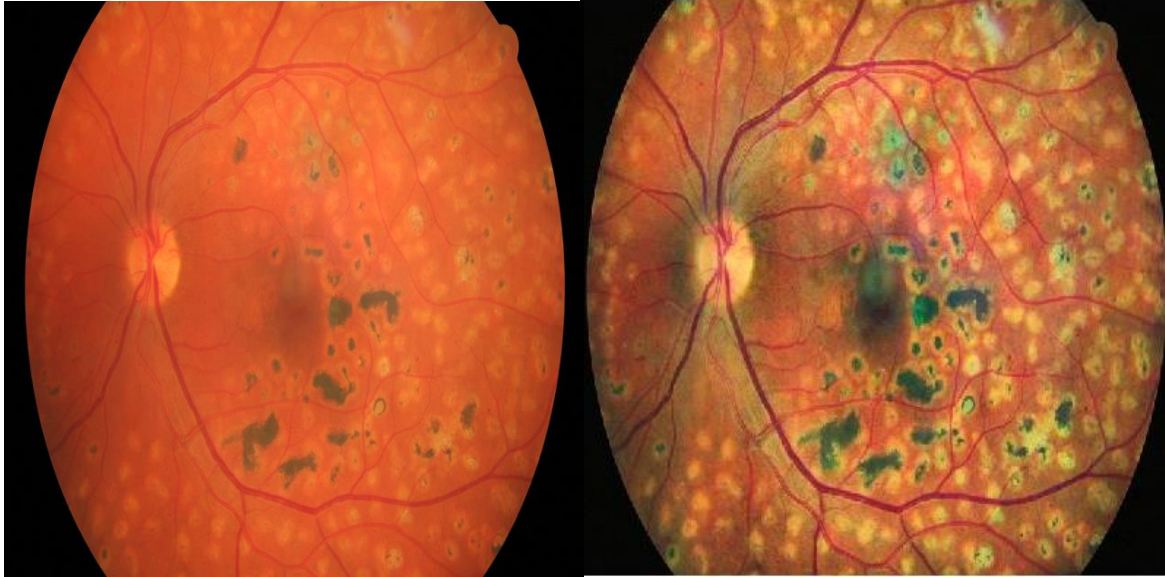
This preprocessing method aims to enhance the contrast of fundus images by applying a gray level transformation using the following operator:

$$f' = \begin{cases} \frac{\frac{1}{2}(f'_{\max} - f'_{\min})}{(\mu - f_{\min})^r} \cdot (f - f_{\min})^r + f'_{\min}, & f \leq \mu \\ -\frac{\frac{1}{2}(f'_{\max} - f'_{\min})}{(\mu - f_{\max})^r} \cdot (f - f_{\max})^r + f'_{\max}, & f \geq \mu \end{cases}$$

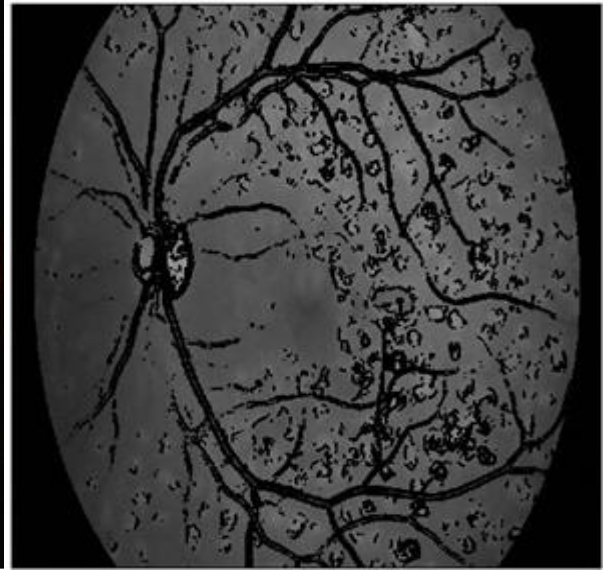
- Where $\{f_{\min}, \dots, f_{\max}\}, \{f'_{\min}, \dots, f'_{\max}\}$ are the intensity levels of the original and the enhanced image, respectively, μ is the mean value of the original grayscale image and $r \in \mathbb{R}$ is a transition parameter.

Possible Outcome

Adaptive histogram equalized color image

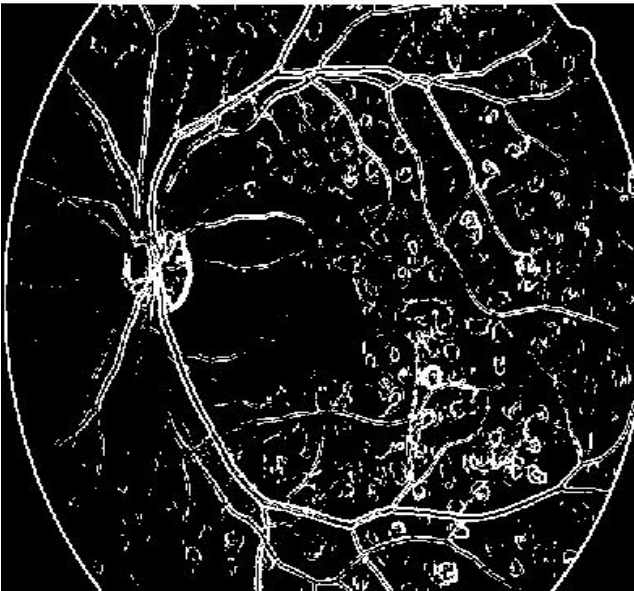


vessel removed image-green channel

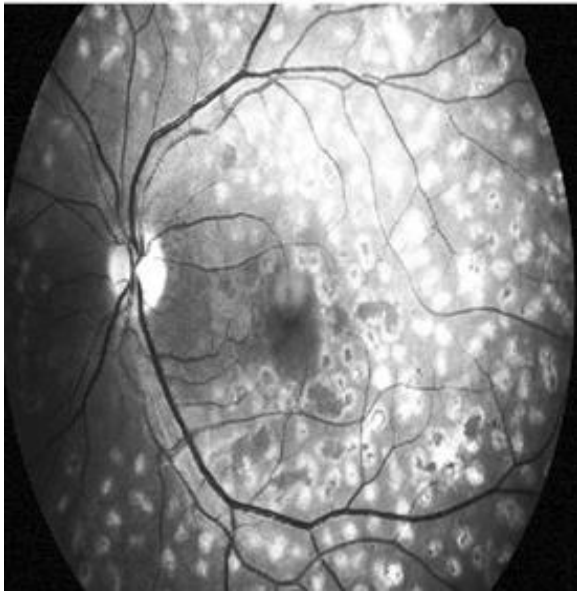


Original image is been process to get clear blood vessels & micro aneurysms

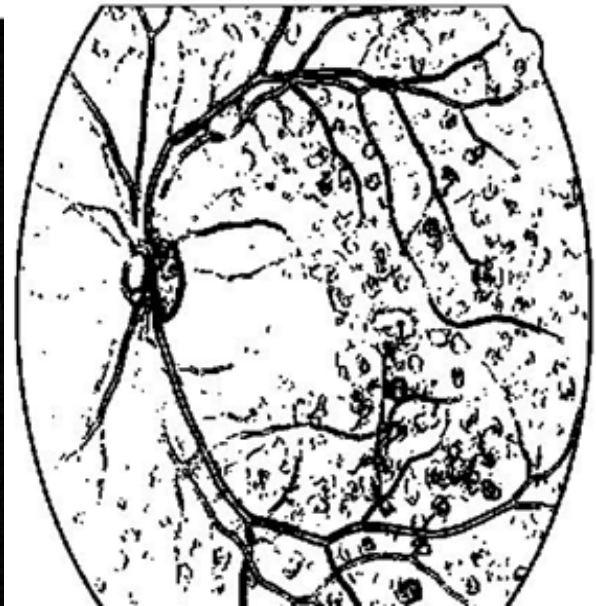
Extracted Blood Vessels-GREEN Binary



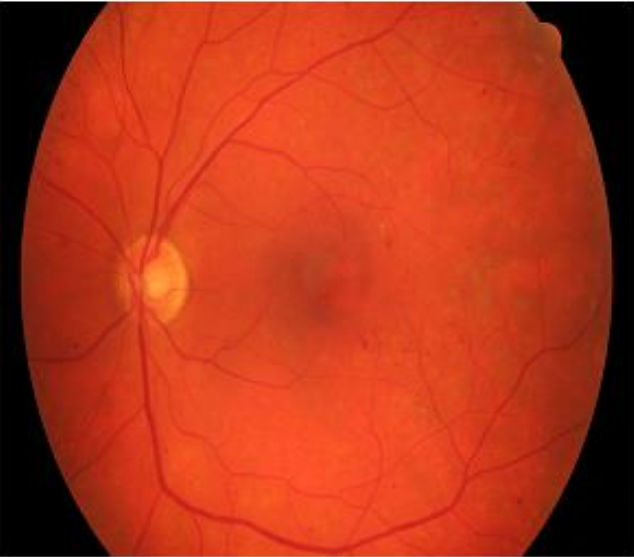
histogram equalized image



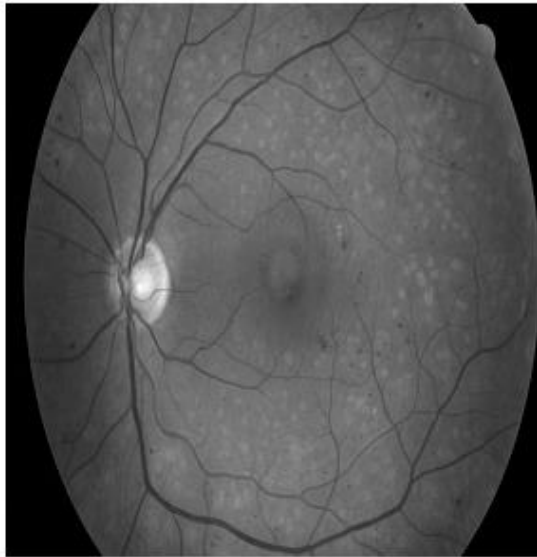
Vessel mask-GREEN



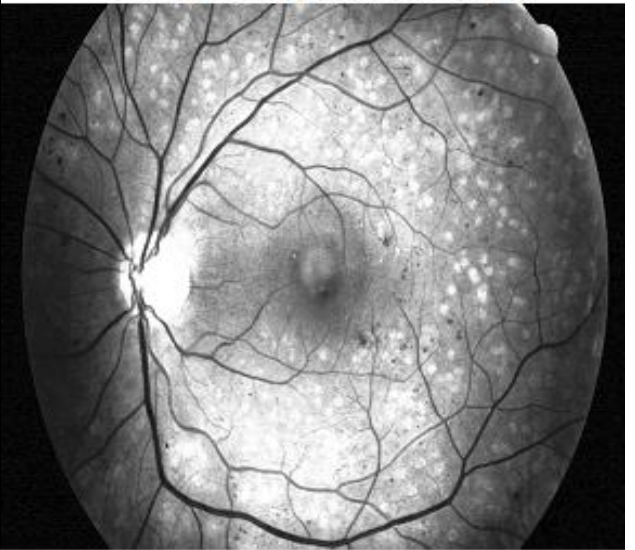original image



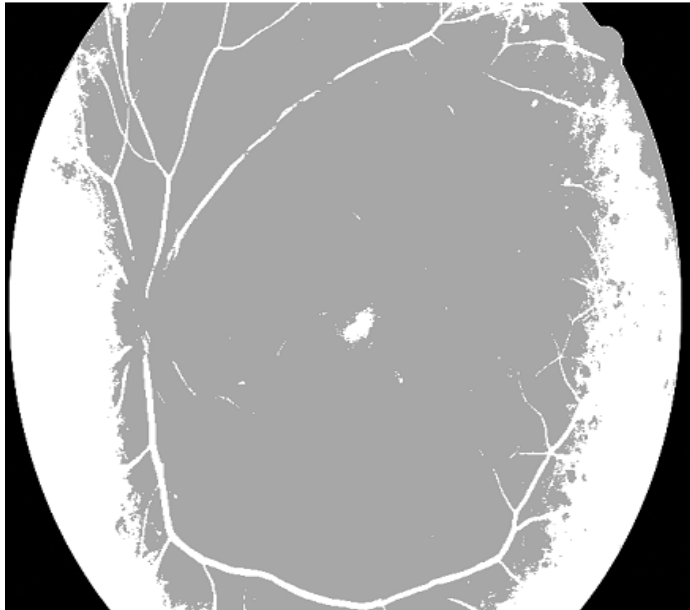
gray image




histogram equalized image



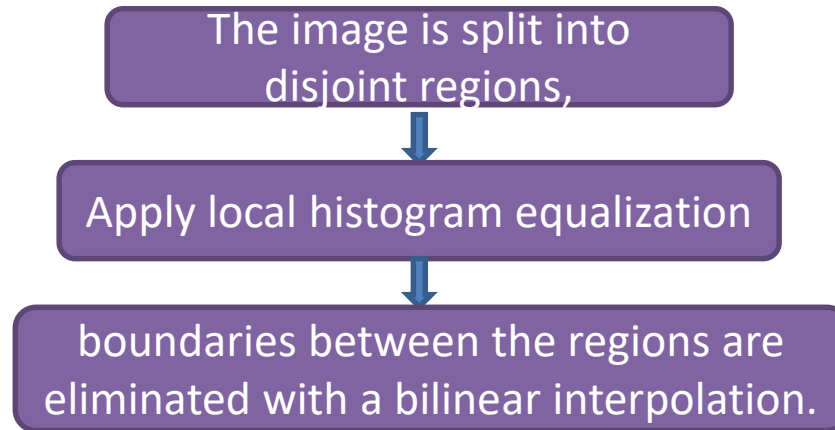
Walter-Klein Contrast Enhancement image



Walter et al image



- **Contrast Limited Adaptive Histogram Equalization (CLAHE) :**
- CLAHE is very effective in making: the usually interesting salient parts more visible.



- **Objective of Method :**

- To define a point transformation within a local fairly large window with assumption that the intensity value within it is a stoical representation of local distribution of intensity value of the whole image. The local window is assumed to be unaffected by the gradual variation of intensity between the image centers and edges. The point transformation distribution is localized around the mean intensity of the window and it covers the entire intensity range of the image.
- Consider a running sub image W of $N \times N$ pixels centered on a pixel $P (i,j)$, the image is filtered to produced another sub image P of $(N \times N)$ pixels according to the equation below

$$p_n = 255 \cdot \left(\frac{[\phi_w(p) - \phi_w(\text{Min})]}{[\phi_w(\text{Max}) - \phi_w(\text{Min})]} \right)$$

- Where

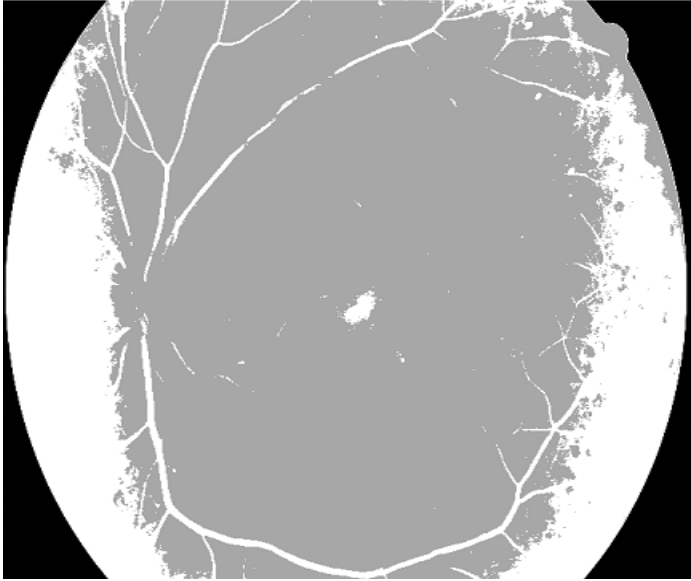
- maximum and minimum intensity values in the whole image, while μ_w and σ_w indicate the local window mean and standard deviation which are defined as:

$$O_w(p) = \left[1 + \exp \left(\frac{\mu_w - p}{\sigma_w} \right) \right]^{-1} \quad \mu_w = \frac{1}{N^2} \sum_{(i,j) \in (k,l)} p(i,j)$$

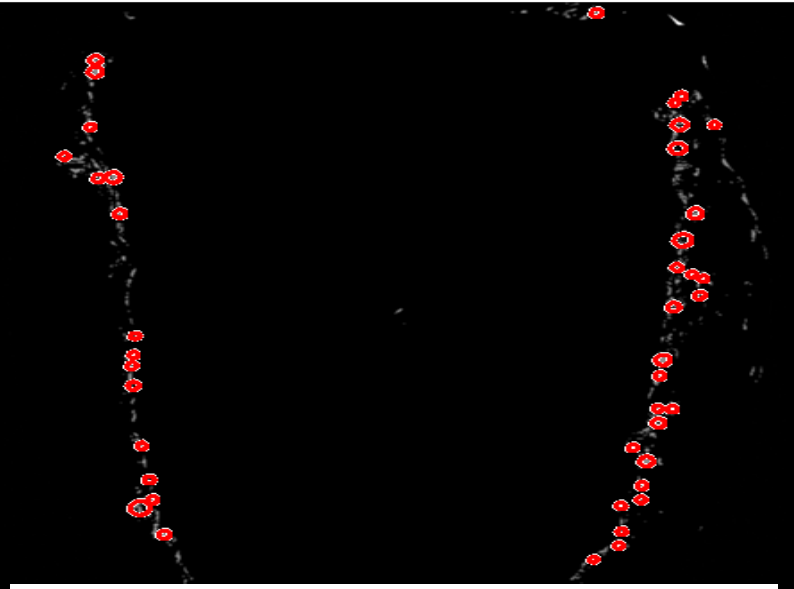
- As a result of this adaptive histogram equalization, the dark area in the input image that was badly illuminated has become brighter in the output image while the side that was highly illuminated remains or reduces so that the whole illumination of the image is same.

$$\sigma_w = \sqrt{\frac{1}{N^2} \sum_{(i,j) \in (k,l)} (p(i,j) - \mu_w)^2}$$

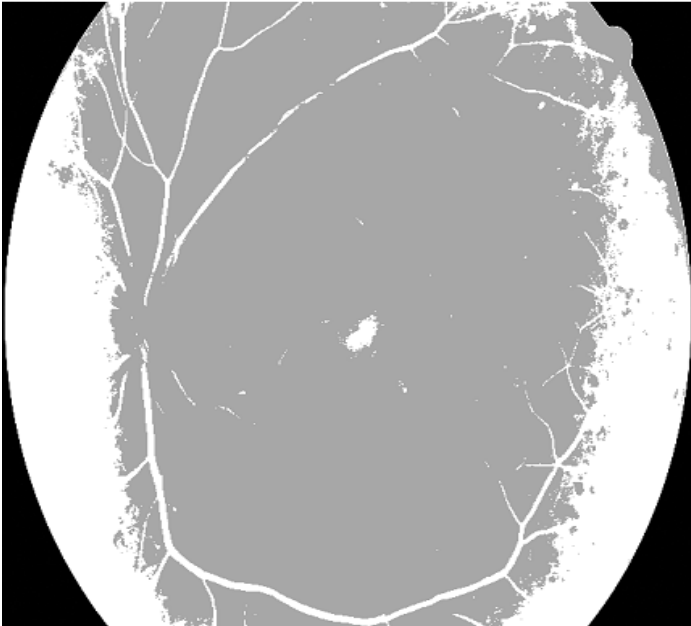
Walter-Klein Contrast Enhancement image



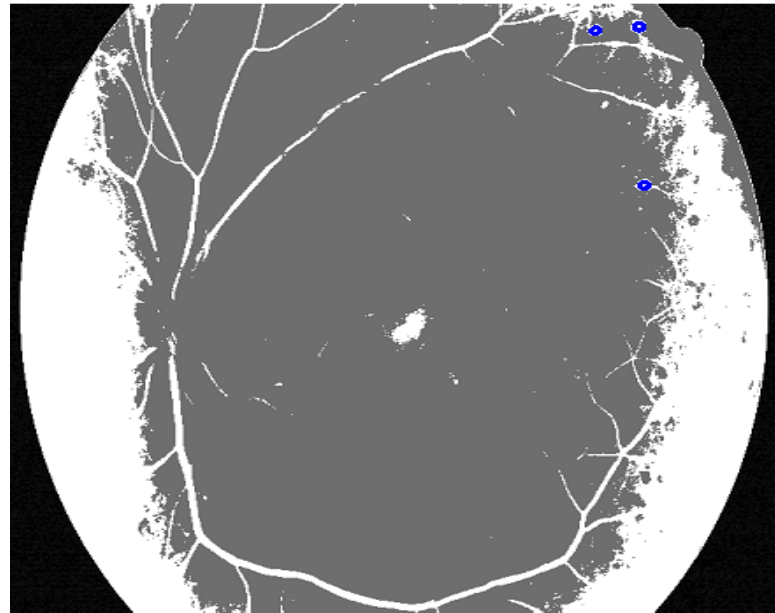
fleming et al image



Walter-Klein Contrast Enhancement image

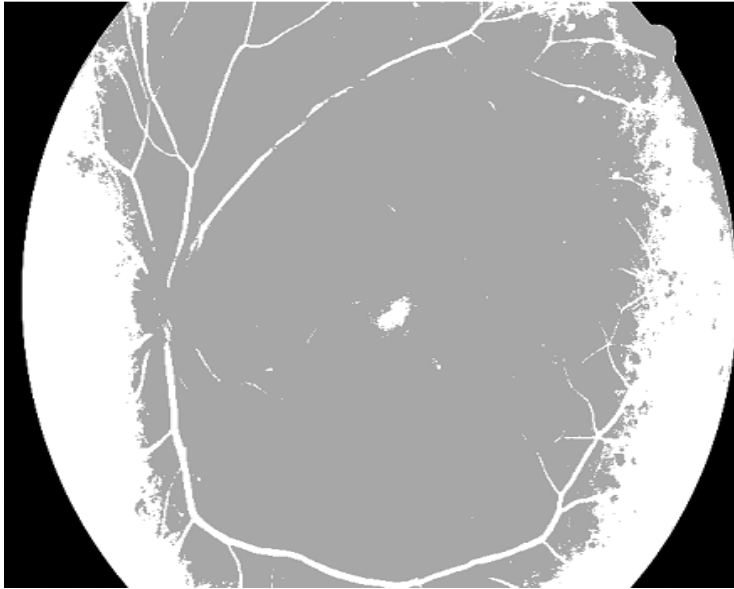


Circular Hough-Transformed image

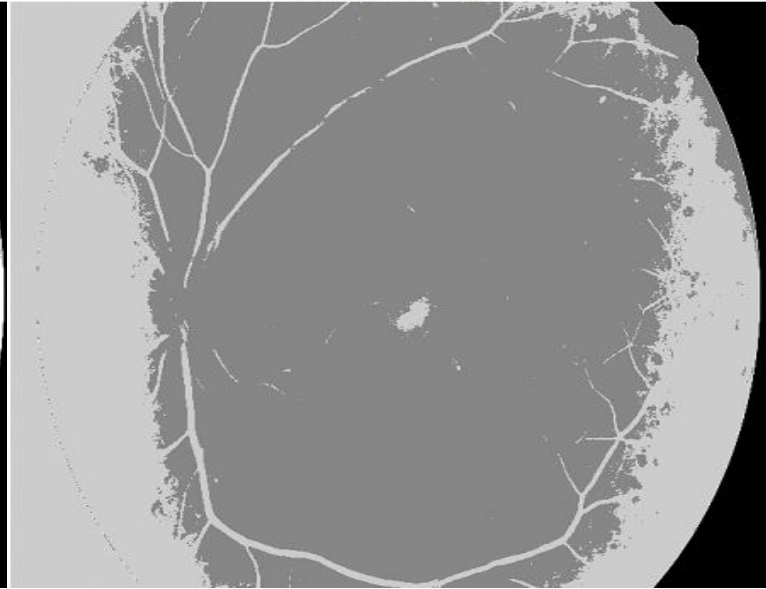


Result 5) :

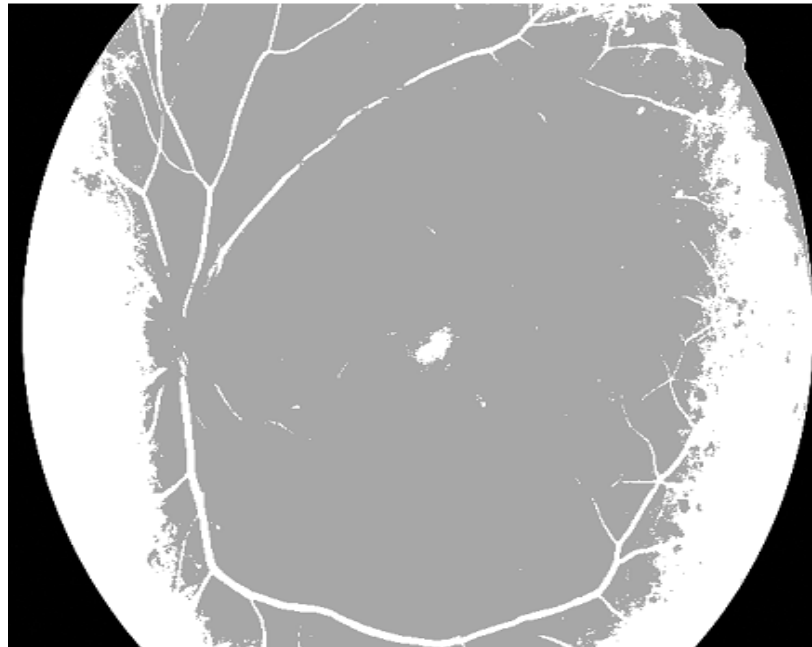
Walter-Klein Contrast Enhancement image



zhang et al image



Walter-Klein Contrast Enhancement image



Result 6):

Diabetic Retinopathy in India

Challenges

- Expensive treatment, Poor metabolic control, Non-awareness
- Affordability : Cost effectiveness Rural population
- Lack of Lab. Facilities & Complex surgical procedures with Unpredictable outcome
- Inadequate facilities for diagnosis, investigation and management of DM – Rural areas
- Vascular complications -No symptoms in stages amenable for treatment
- Available ophthalmologists are less

Social Impact

- Patients can get treatment in early symptoms of Retinopathy.
- Patients will get fast detection results with affordable treatment.
- This project can improve the ability for early detection DR and their progress based on new imaging techniques.
- Ophthalmologists can judge image data. like an automated segmentation and thickness measurement of the nerve fiber layer

Diabetic Retinopathy Detection

MAJOR DISEASE GOING TO BE DETECTED:

1)MICRO –ANEURYSM, 2)GLAUCOMA

STEPS FOR VESSEL DETECTION

- Input Image
- Preprocessing
- Vessel Extraction Algorithm
- Extracted Vessels

STEPS FOR MICRO –ANEURYSM DETECTION

- Input Images (Training)
- Implementing 5 Algorithms For Preprocessing
- Implementing 5 Algorithms For Candidate Extraction
- Apply The 25 Combinations
- Quantity Analysis (Entropy)
- Best Combination Selection
- Input Image (Testing) Reprocessing)

CANDIDATE EXTRACTION (SEGMENTATION)

MICRO ANEURYSM DETECTION

PERFORMANCE MEASUREMENTS

- ✓ sensitivity,
- ✓ specificity,
- ✓ accuracy,
- ✓ shape features [such as Area' Perimeter Eccentricity Centroid],
- ✓ MajorAxisLength , MinorAxisLength

CLASSIFICATION OF THE PATIENT CONDITION

Normal, Mild, Moderate, Severe

STEPS FOR GLAUCOMA DETECTION

1. Input Image .
2. Preprocessing.
3. Optic Disk Segmentation.
4. Optic Cup Segmentation Area .
5. Cup To Disk Ratio.
6. Glaucoma Detection.
7. Classification Of The Patient Condition.
8. Performance Measurements.

Conclusion

- ❑ DR is extremely asymptomatic disease in the premature stages and it could lead to lasting vision loss if untreated for long time. Before patients reaching to last stage ophthalmologist can detect the disease precisely & can avoid vision loss, using Image Processing Technique.
- ❑ Outcomes will become available in terms of accurately tracking or monitoring the patient specific evolution of DR.
- ❑ The severity of DR the area of these features will be calculated. Based on the results of area computation, the system uses the classification as normal, mild, severe to identify the stages of non-proliferative DR and proliferative DR.

Results achieved :

- 1) The concept of Canny filter detection of signals is used to detect piecewise linear segments of blood vessels in images.
- 2) Algorithm of Gaussian filter is capable to detect looping structure in the blood vessel which is to manifestation of abnormal symptom.
- 3) MA candidate extraction
- 4) Median Filters can be very useful for removing noise from images.
- 5) Fuzzy Gaussian Filter feature extraction of images. It is very essential to extract infected blood vassals to diagnose early therefore filtering is frequently utilized in image processing
- 6) Smooth noise & to enhance or detect features within an image. To improve quality of image linear & non-linear method may be used.